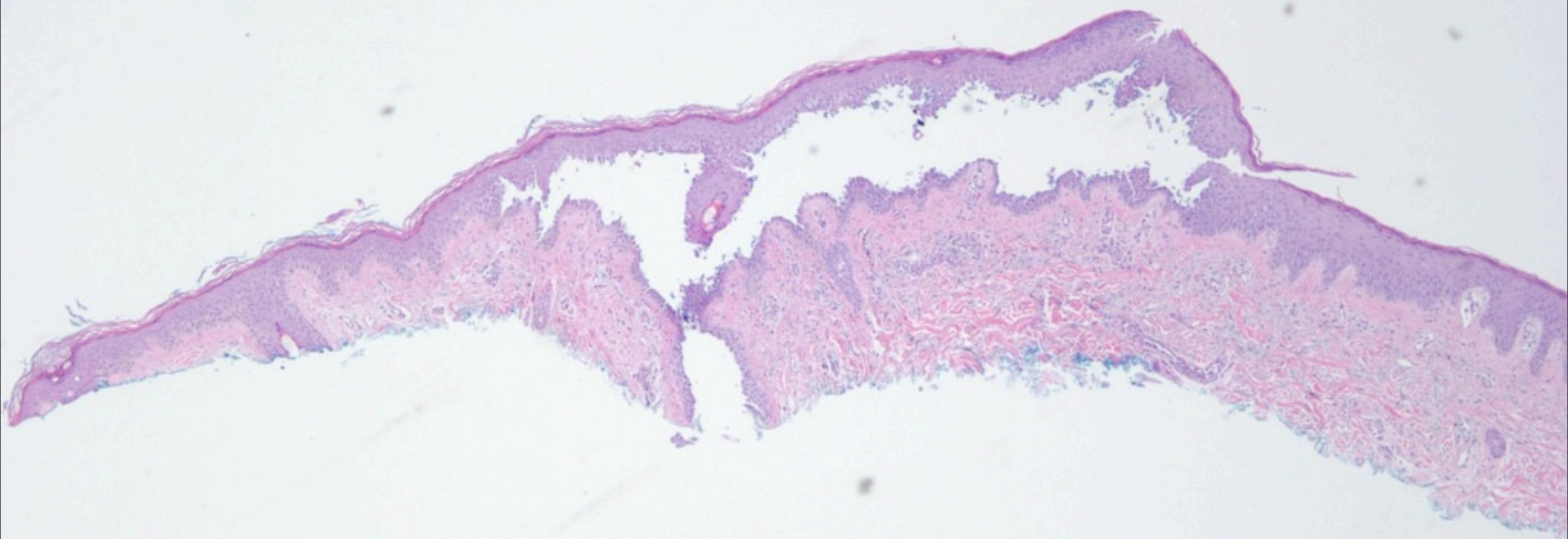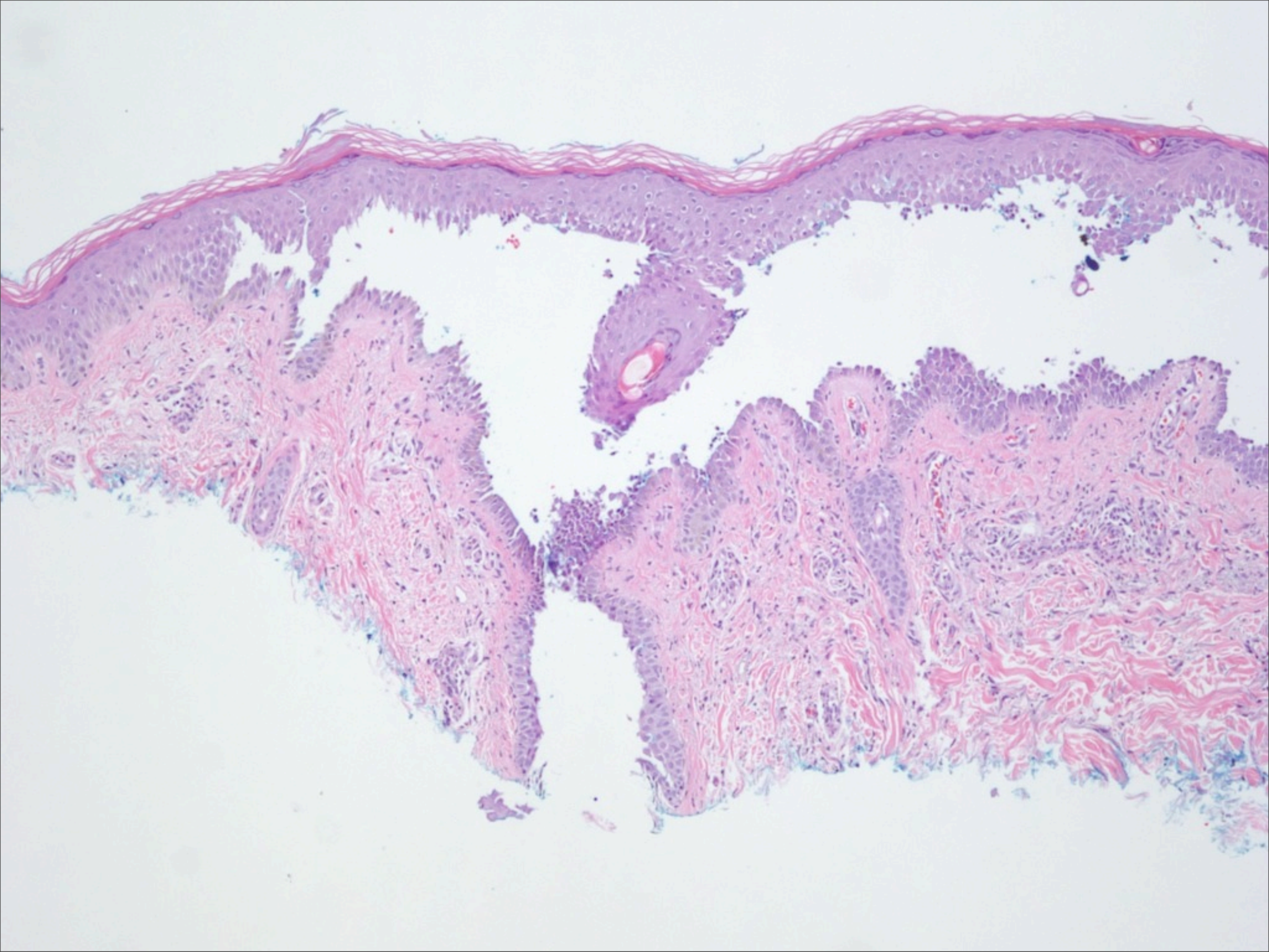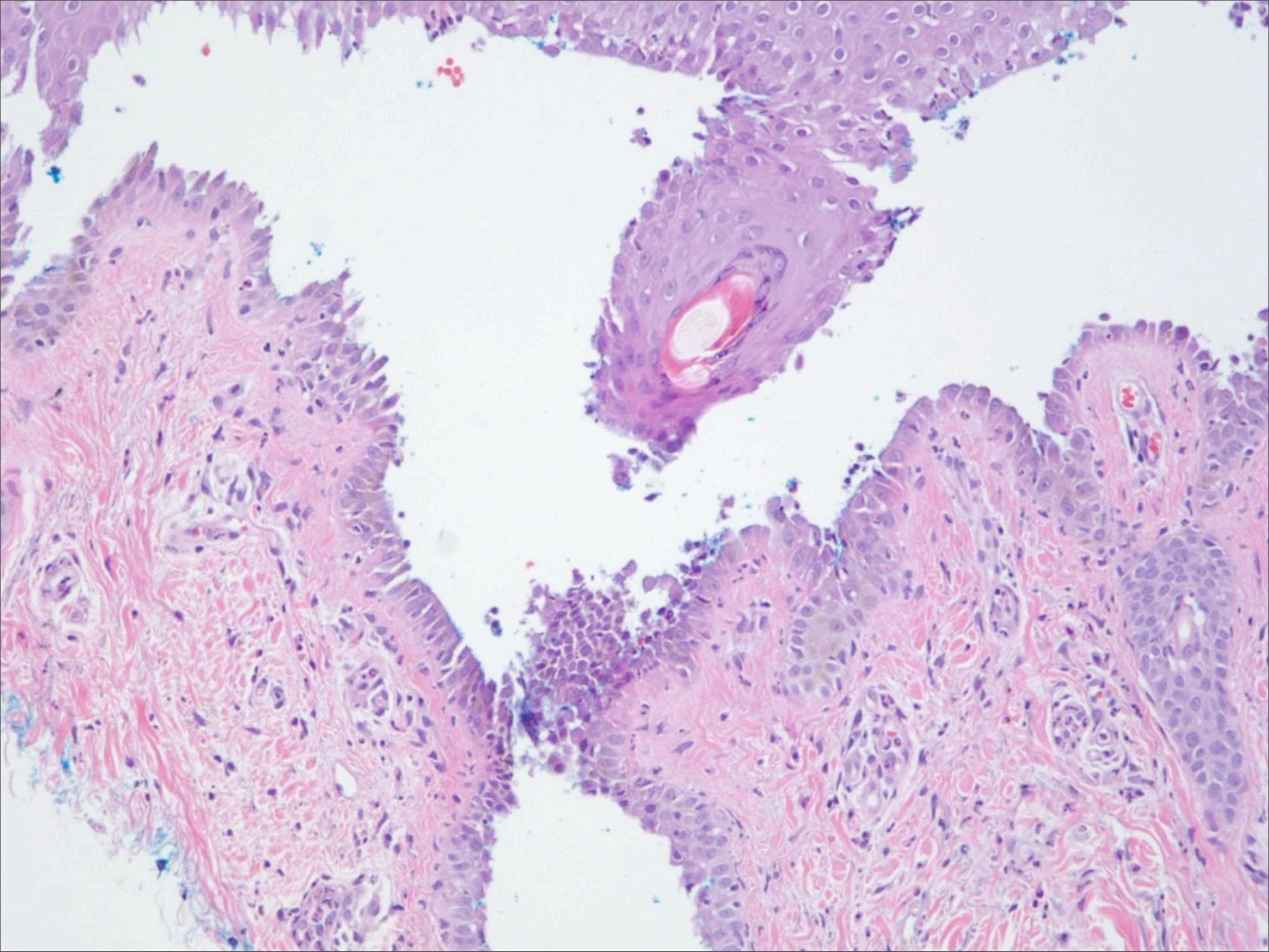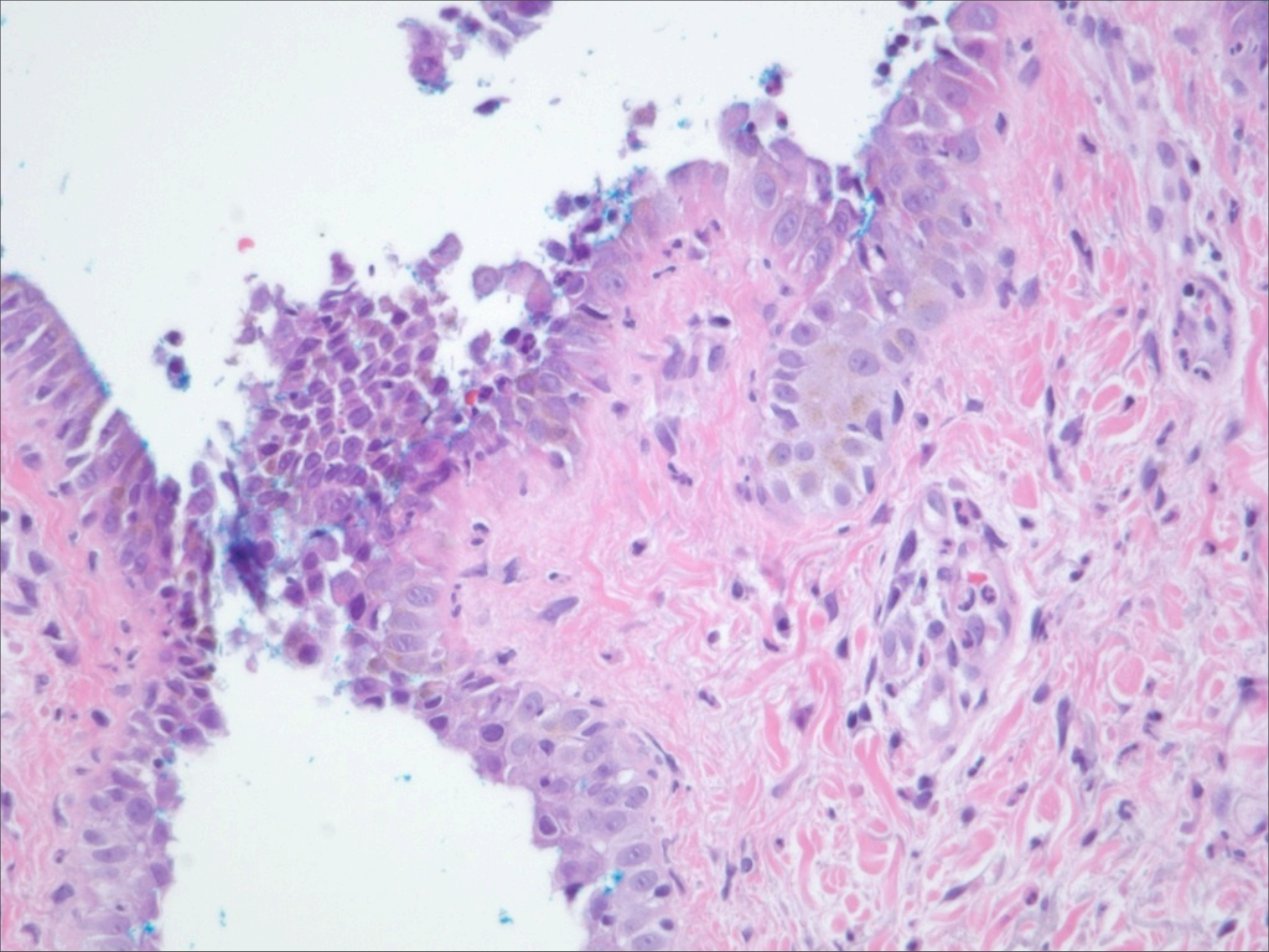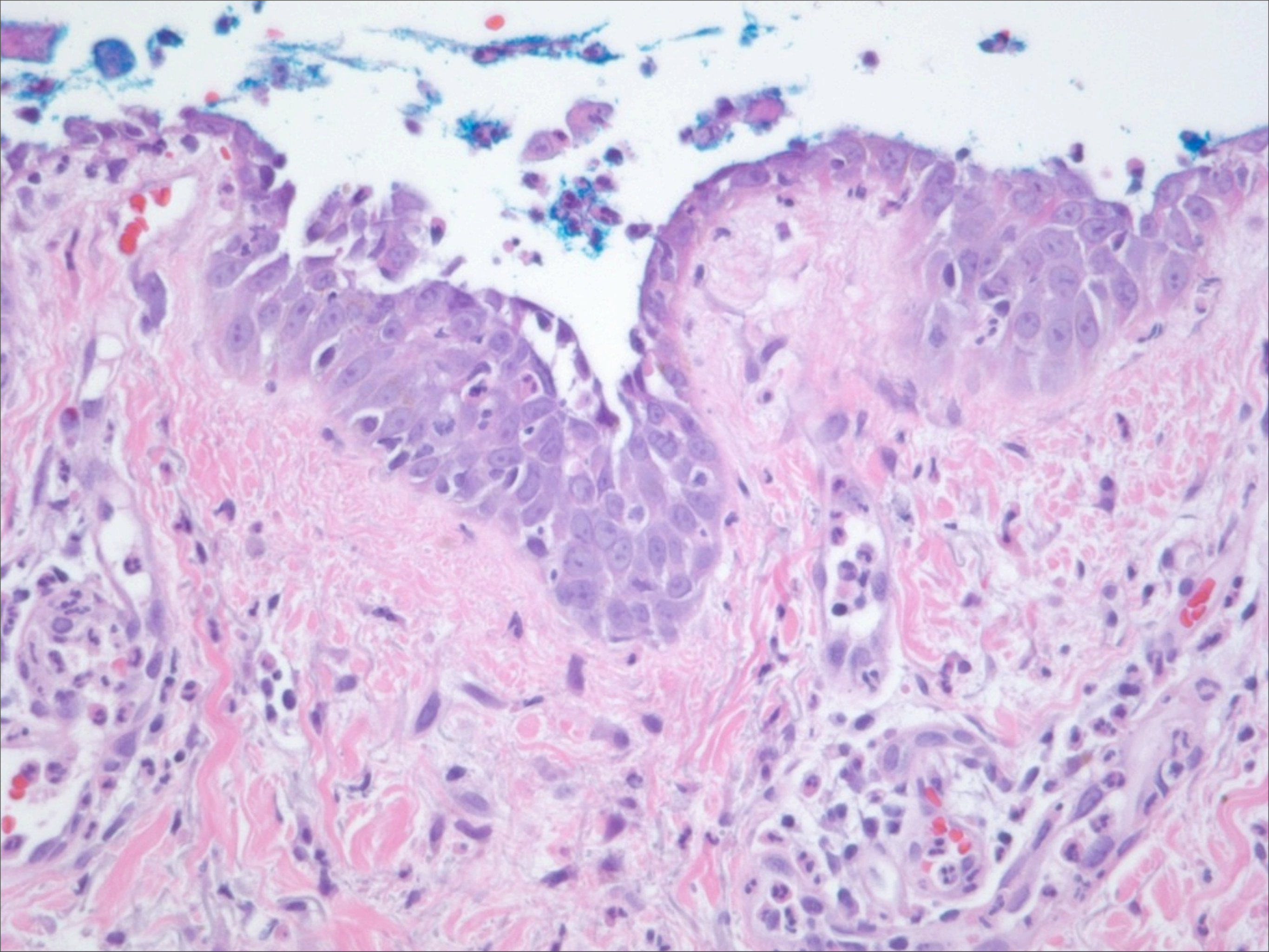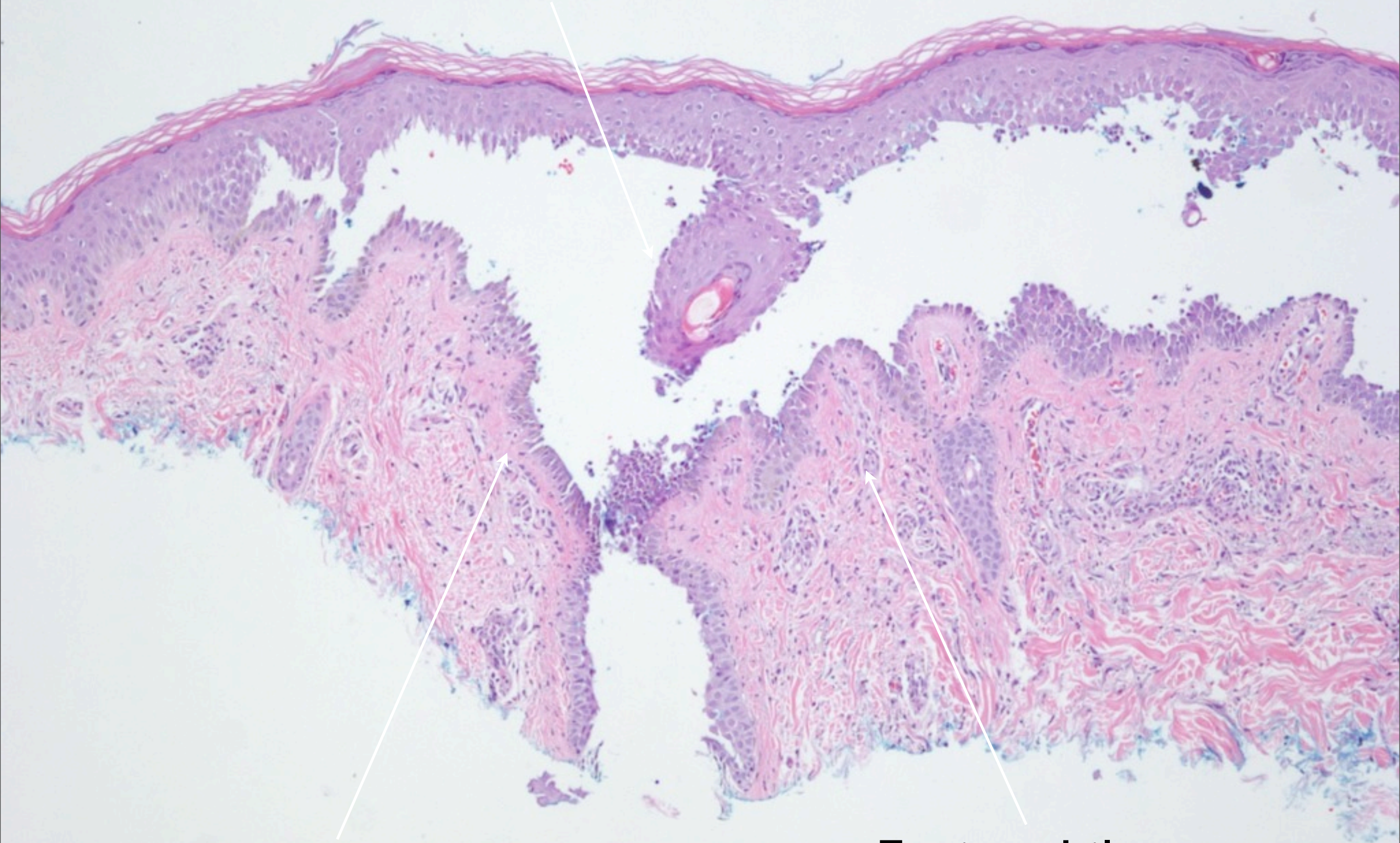


Pemphigus vulgaris

Acantholysis extends along follicular epithelium



Suprabasilar Acantholysis

Eosinophils